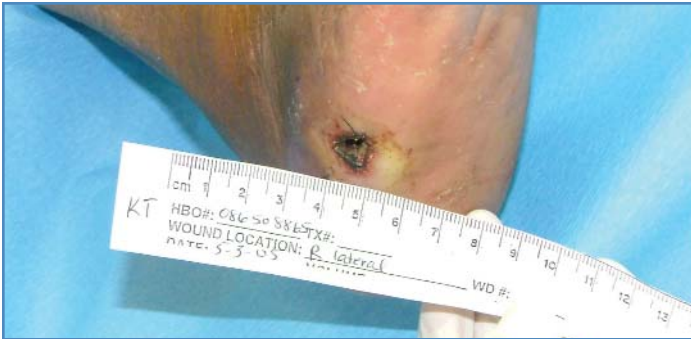
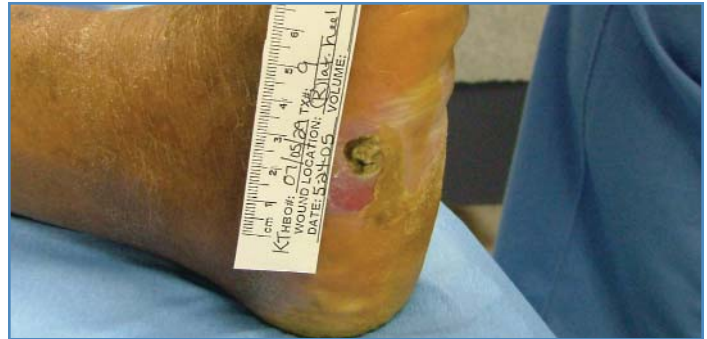
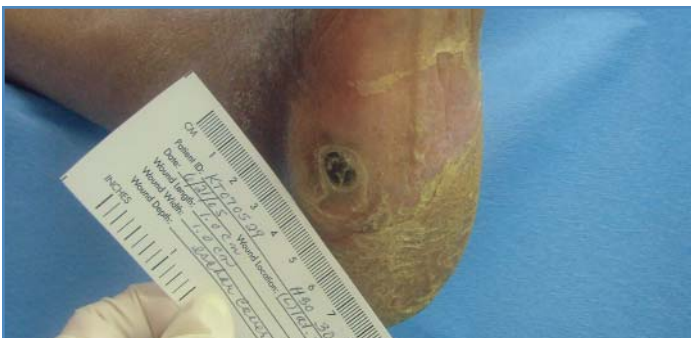
Hyperbaric Oxygen Treatment for Chronic, Non-Healing Wound – Right Foot



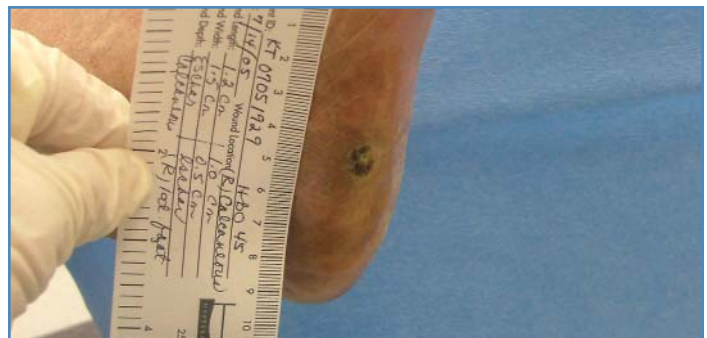
Initial Visit



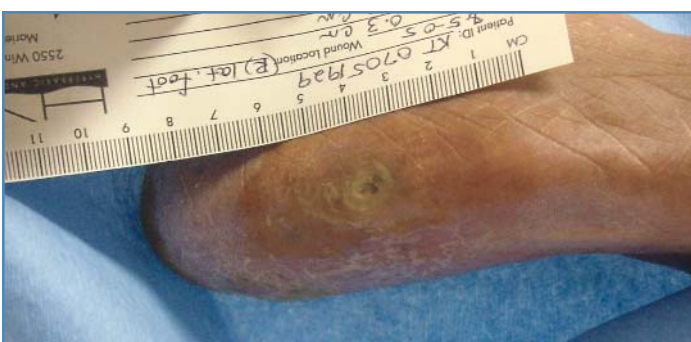Treatment 5



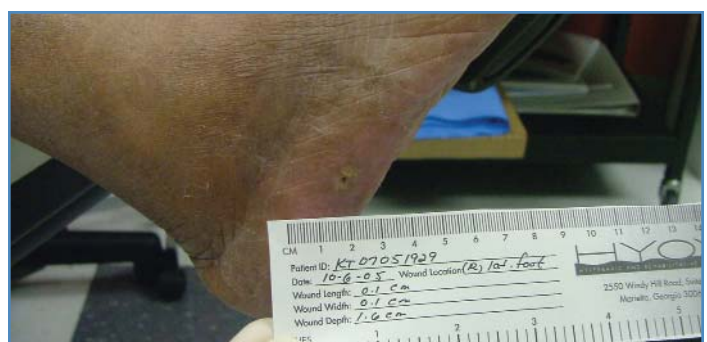Treatment 30



Treatment 45



Treatment 60



Treatment 71

The patient, a 75-year-old female with diabetes, was presented to HyOx with a chronic, non-healing diabetic foot wound. She underwent an evaluation of her vascular system that showed severe multi-level occlusive disease of the right leg with femoral, popliteal and tibial occlusions. She was also to have left superficial femoral artery stenosis at the adductor canal, left mid popliteal artery occlusion and severe tibial artery occlusive disease on the left leg with an anterior tibial artery patent only by collaterals just above the ankle. The patient then went on to have an I&D and removal of foreign body from the right lateral foot wound. The patient participated in 71 hyperbaric treatments. End Result: The patient did very well and was able to walk again with an orthotic shoe. Her pain also was resolved. She is ambulating with an orthotic shoe. The patient did not require any further surgery and was discharged to home.