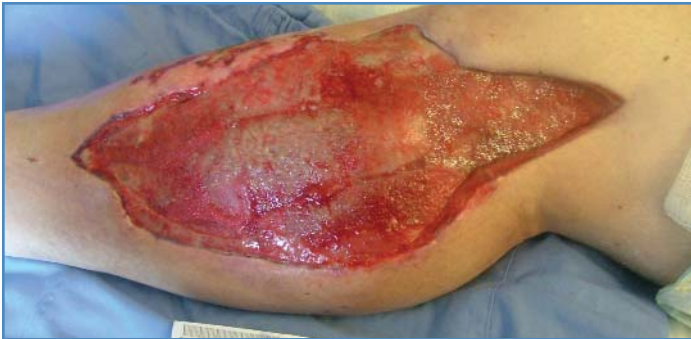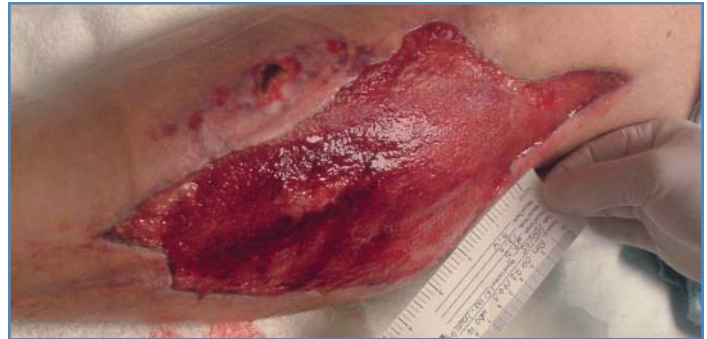


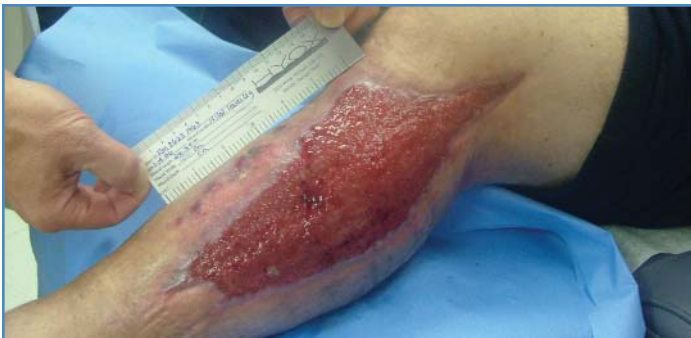Hyperbaric Oxygen Treatment for Necrotizing Fasciitis – Left Lower Extremity



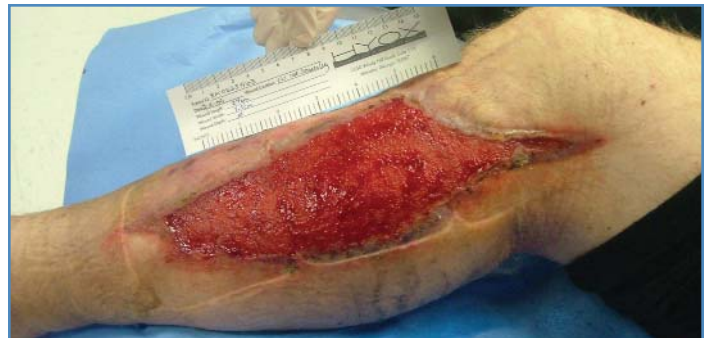Treatment 9



Treatment 14



Treatment 18



Follow-up Visit

The patient, a 42-year-old male, was presented to HyOx with necrotizing fasciitis of the left lower extremity after a crush injury in October 2005. The patient participated in 18 hyperbaric treatments from 11/29/05 through 12/23/05. End Result: The patient did well with hyperbarics and continued to show good healing. The patient had an Apligraf applied. He showed good granulation tissue over the wound and began epithelialization. He was able to ambulate with a crutch in the right arm. If at a later date he had a further need for skin grafting and needed help healing the flap, a re-evaluation for hyperbarics would be conducted.